

CURRICULUM VITAE

Name: Dr. Garikala Chandrakala, M. D. S

Phone No: 9441961461

Date of Birth: 18-12-1991

Email ID: kalagarikala@gmail.com

Address: MIG 147, APHB colony, Gachibowli Hyderabad, Telangana, 500032.

EDUCATION:

➤ **Bachelor Of Dental surgery (B.D.S)**

1. Date of passing: 2015
2. Internship: from oct 2014 – oct 2015
3. College: Govt Dental College and Hospital, RIMS, kadapa
4. University: NTR University
5. Reg No: A17584

➤ **Master Of Dental Surgery (M. D. S)**

1. Department: department of periodontics and implantology
2. Date of passing : 2019
3. College: G. Pulla Reddy Dental College And Hospital, kurnool.
4. University: NTR University

JOB PROFILE:

- Good theoretical knowledge
- Good knowledge about clinical practice and protocol
- Good a diagnostic skills
- Ability to handle different types of patients
- Good skills on cases
 1. Conventional and advanced laser flap surgeries with bone grafting procedures.

2. Root canal treatments of anterior and posteriors: Conventional and rotary.
3. Crown cuttings anterior and posterior: single unit and multiple units.
4. Smile designing
5. Aesthetic procedures: crown lengthening, teeth whitening (bleaching), composite restoration for spacings
6. Extraction of wisdom tooth

EXPERIENCE

- Part time: 8 months of experience in general dentistry in city dental hospital, Kadapa
- Completed senior residency (S.R) in Osmania govt dental hospital from Sep 2019 Sep 2020
- Consultant periodontist in Hyderabad, Kurnool, Adhoni, Kadapa
- 6 months in Partha dental Hospitals.
- Managed a clinic for 2 years for lease.

PUBLICATIONS:

- Limiting the placebo and Hawthorne effect in periodontal clinical trials: Current concepts and future direction.

Journal of research and advancement in dentistry 2018: 7:3:137-145.

CONFERENCES AND WORK SHOPS ATTENDED:

- 21st to 23rd October, 2016 -- 41st National conference of ISP at Nagpur
- 7th August 2016 – National workshop on growth factors in Army dental College., Hyderabad.
- 24th to 26th March, 2017 -- 16th ISP convention at Manali
- 24th to 26th, November 2017 -- 41st National conference of ISP at Kolkata
- 24th November, 2017 -- Pre-conference course on “Laser-new revolution in

periodontology at 42nd ISP at Kolkata

- 17th and 18th February, 2018 -- State conference by Asian congress of oral implantology, Hyderabad
- 16th to 18th March, 2018 -- 17th ISP PG convention held at Chennai

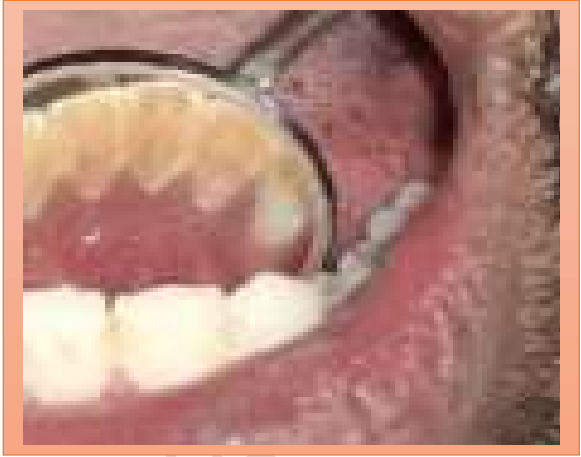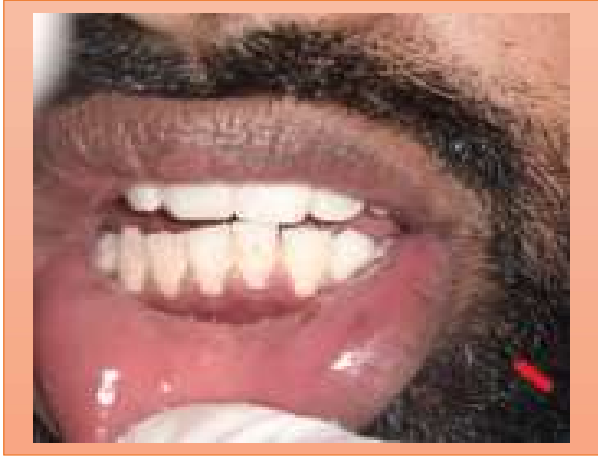10th March 2018 Pre-conference course "soft tissue expanders and management of HAP during ridge augmentation at 17th ISP National PG convention at Saveetri Dental college, Chennai

PRESENTATIONS:

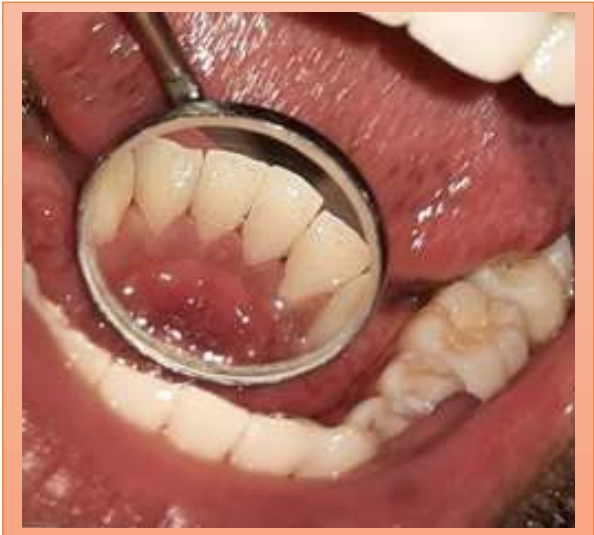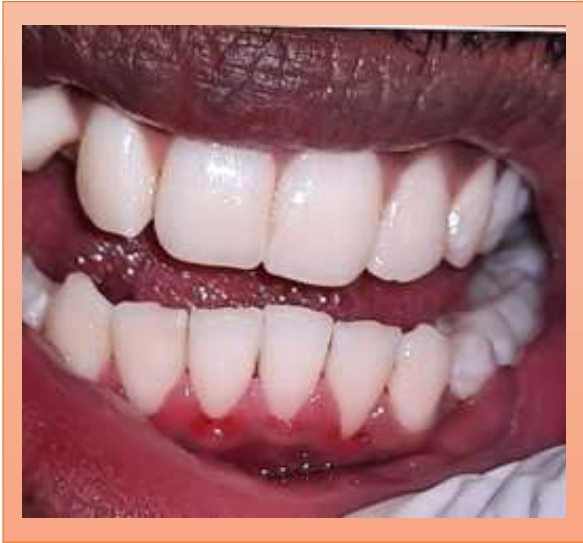- 22/10/2016 Poster: Advanced microbiological diagnostic aids , Nagpur.
- 24/03/2017 Poster: To evaluate the gingival health status of dental students – using 3 different herbal extracts. Manali
- 25/11/2017 Poster: Clinical Evaluation of coronally advanced flap with two different techniques in the treatment of multiple gingival recessions: A pilot study. Kolkata
- 18/03/2018 Poster: The effect of non-surgical periodontal therapy on gingival crevicular blood and peripheral blood glucose levels in diabetic patients with chronic periodontitis Chennai.
- 18/01/2019 Paper: Multi-disciplinary approach for management of periodontally weakened non- vital tooth. Navi Mumbai.

Treatment Cases

SCALING:



BEFORE

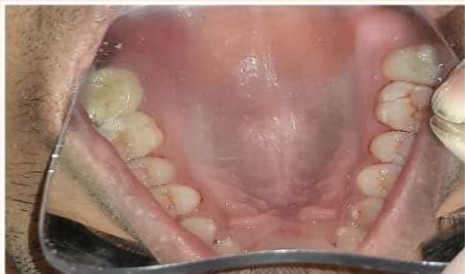
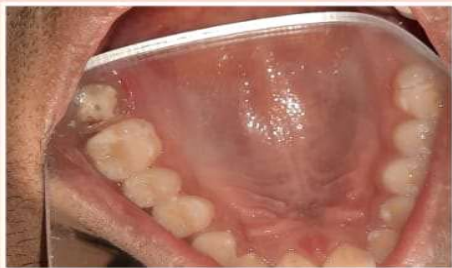
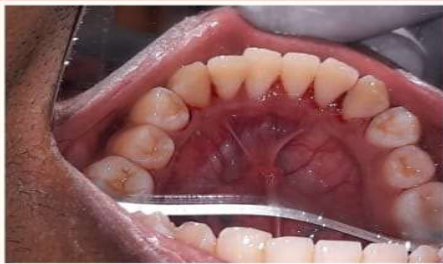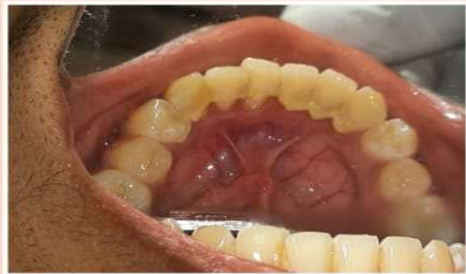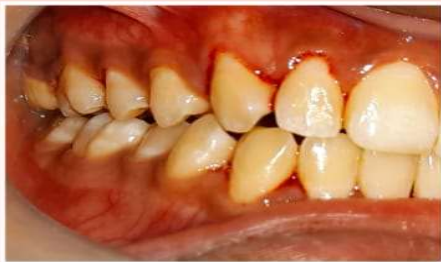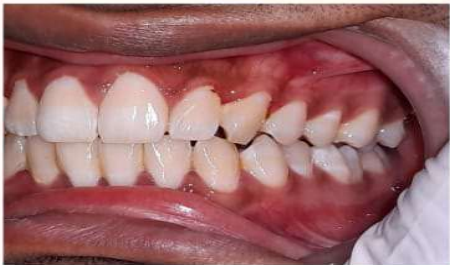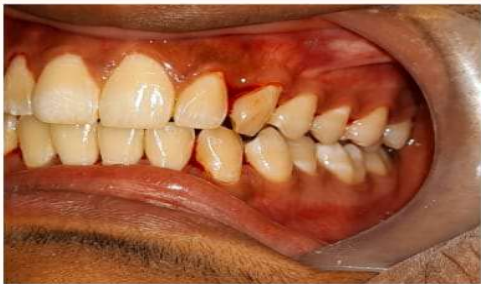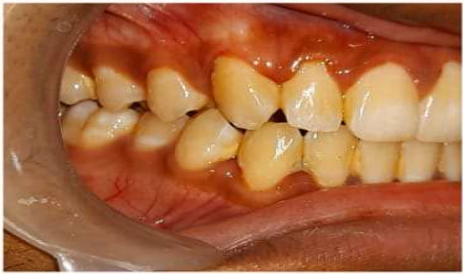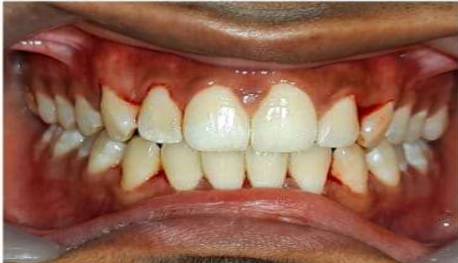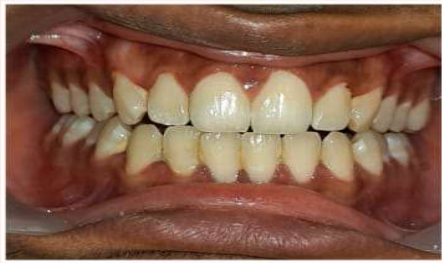AFTER

SCALING AND Zr Crown i.r.t to 17

BEFORE

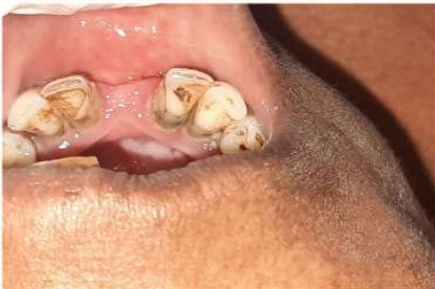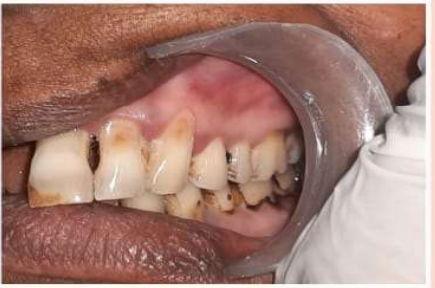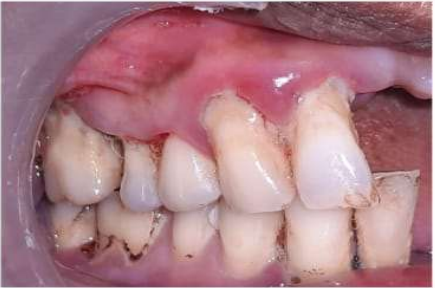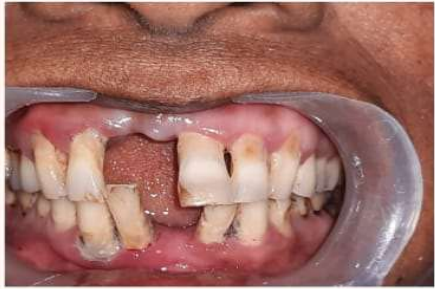AFTER



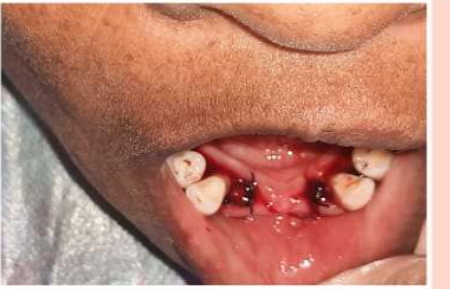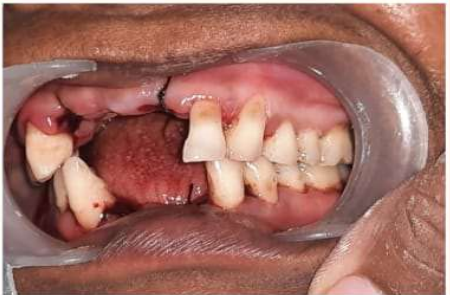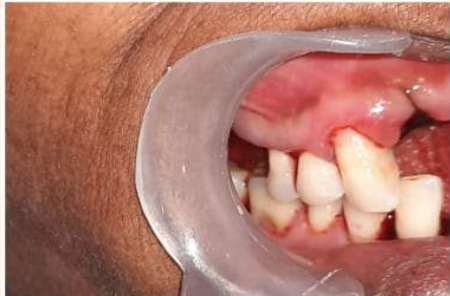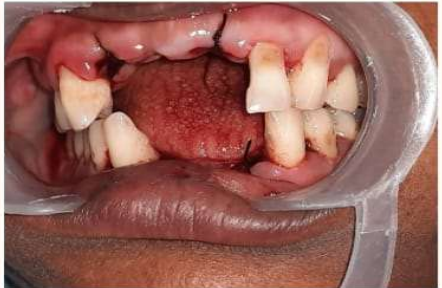SCALING AND CROWN PREP AND ZR FPD IRT 17

Laser Curretage

BEFORE



IMMEDIATE POST OPP

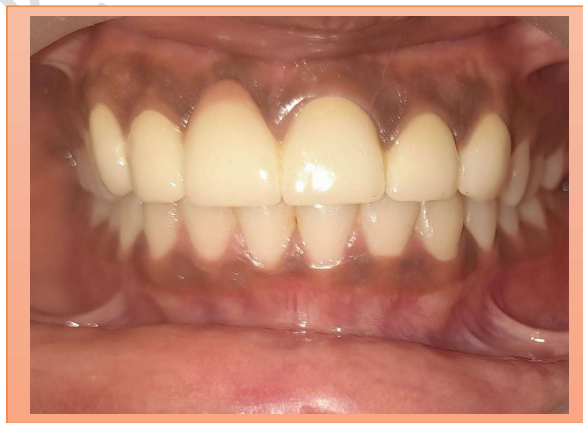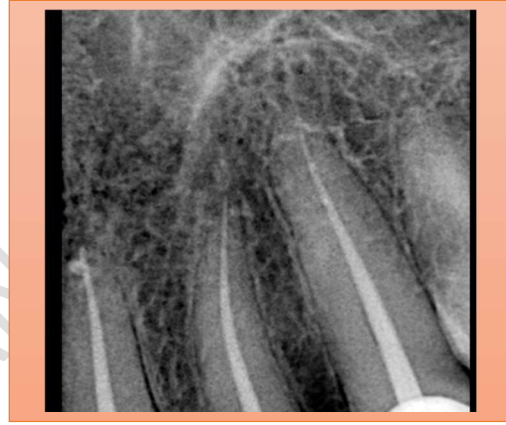

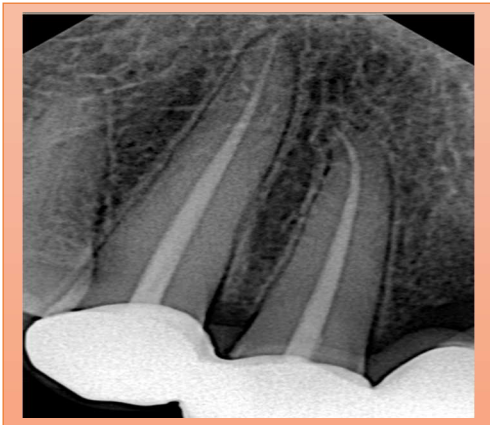
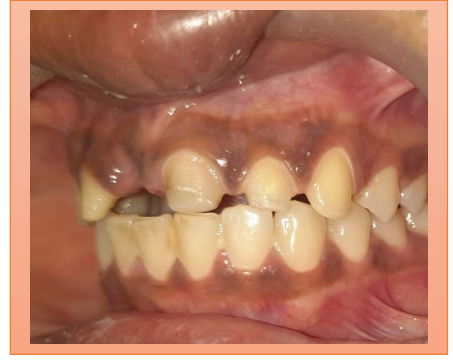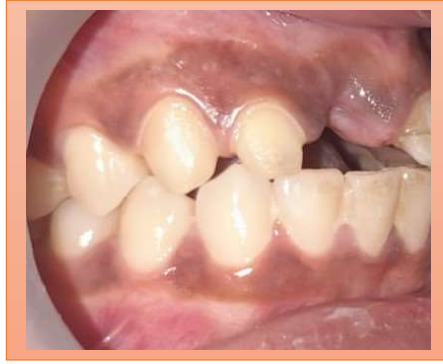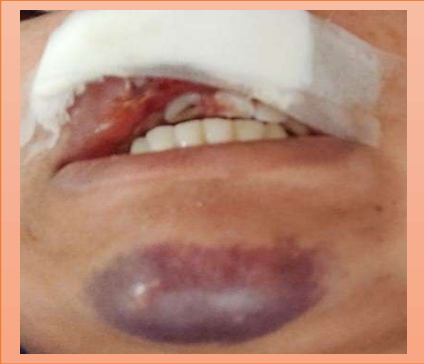LASER CURRETTAGE

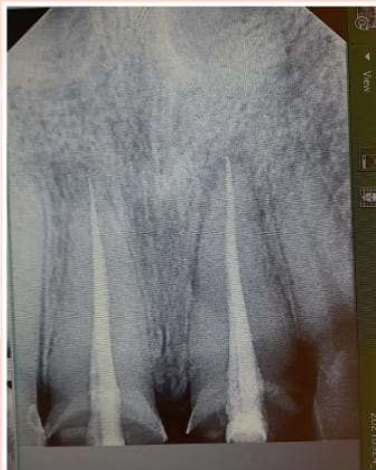
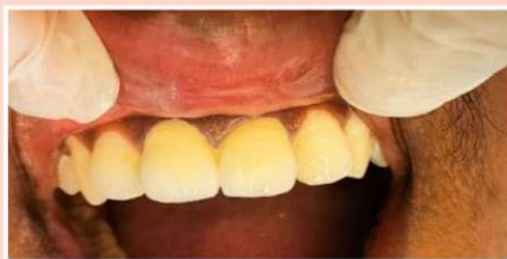
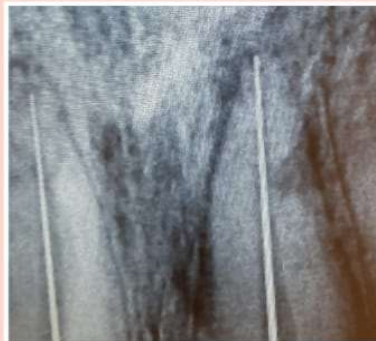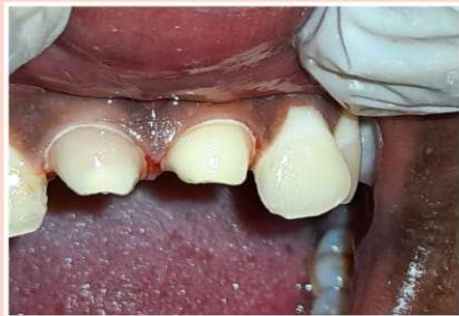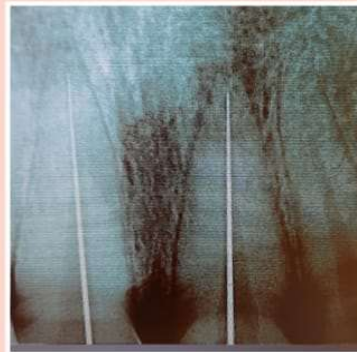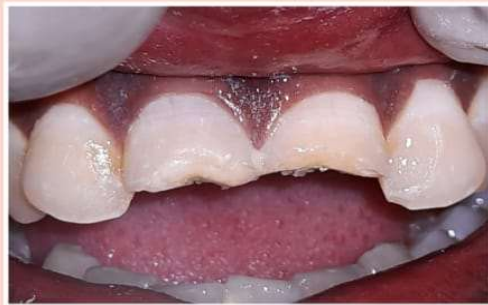**EXTRACTION OF 12, 21, 32, 38, 42
AND 48**

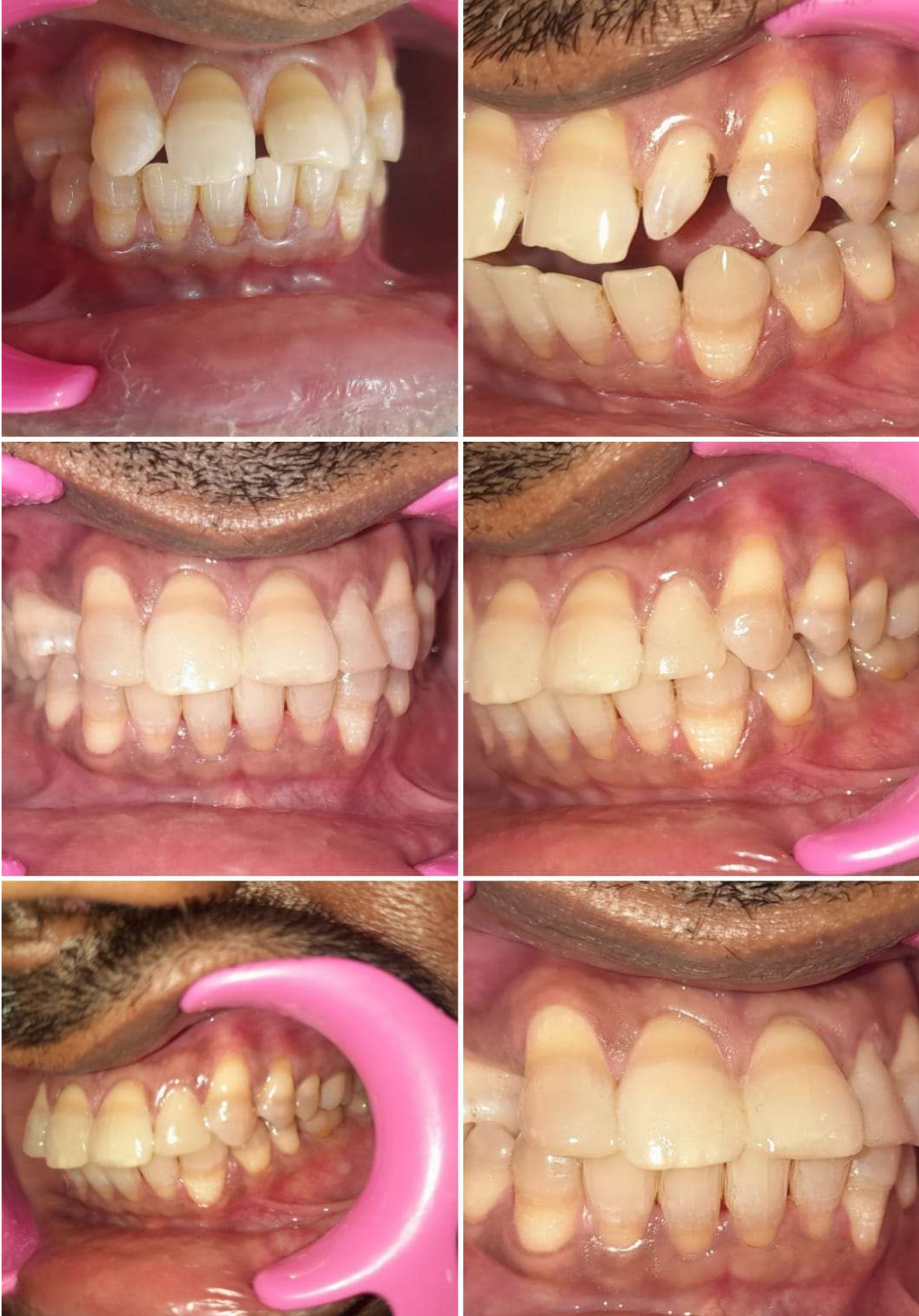treatment and zirconium crowns



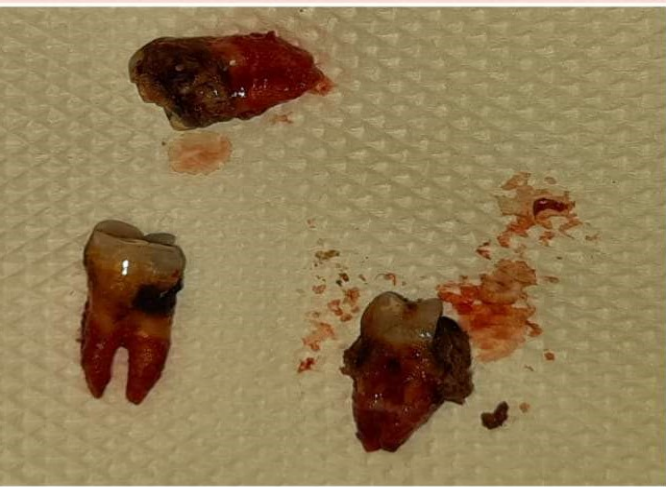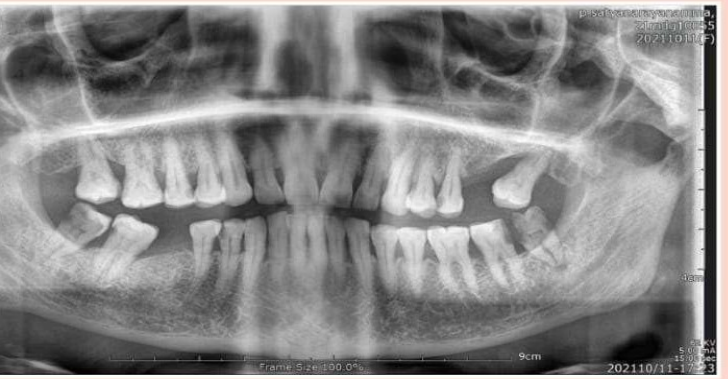Trauma Case---Root Canal Treatment And Pfm Crowns



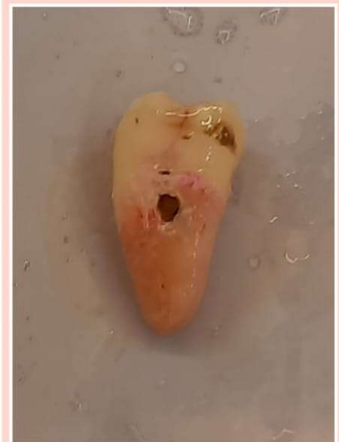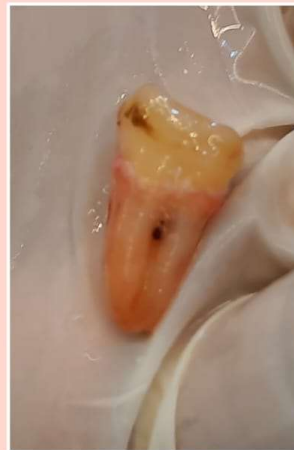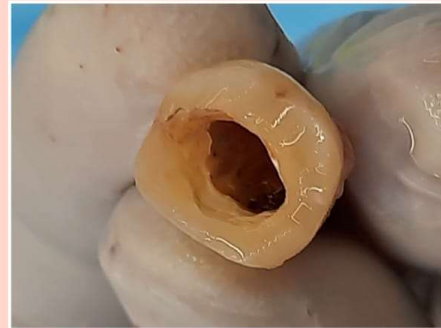
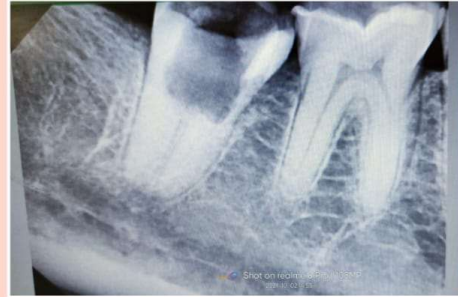
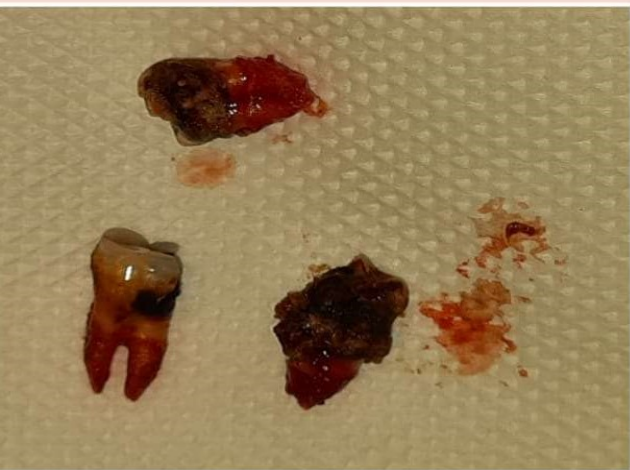Direct Composite Veneer Build Up



EXTRACTION

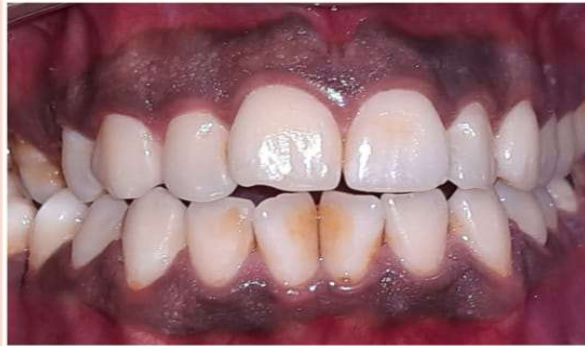

EXTRACTION OF 37, 38 AND 48



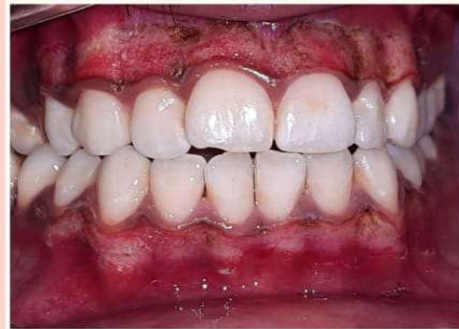Extraction of perforated 47

Gingival Depigmentation

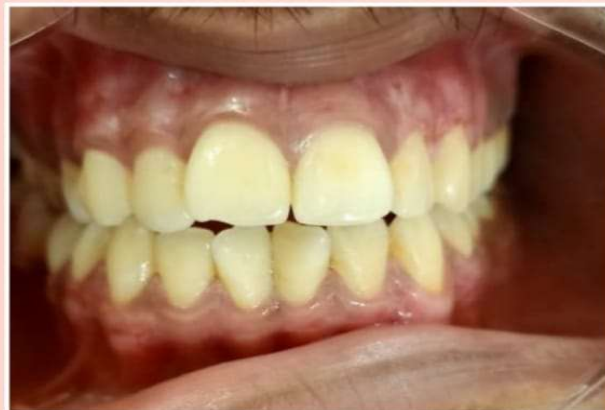

PRE OPP

POST OPP

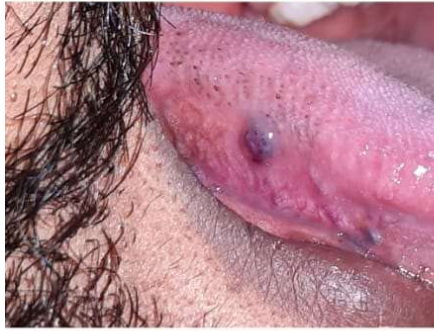

GINGIVAL DEPIGMENTATION



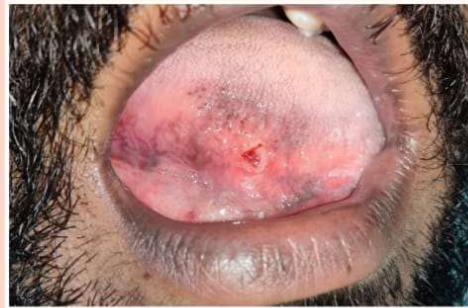**AFTER
1WEEK**

Biopsy case



PRE OPP

**1 DAY AFTER
EXCISION**



**NARAYANA
DIAGNOSTICS**

Name: Mr. NAREESH UMR NO: PKP0915858
Age / Gender: 25 Years / Male Registered on: 30-Sep-2021 08:37 PM
Ref. Dr.: LN DENTAL Reported On: 04-Oct-2021 08:39 AM
Req. No.: XXXP0130807

DEPARTMENT OF SURGICAL PATHOLOGY

LAB NO: 13403 / HPE / 2021

Brief clinical history: ---

Nature of specimen: Biopsy for HPE

Gross: Received single grayish white to grayish brown soft tissue bit is measuring 0.3 cms in size. (ALL EMBEDDED)

Microscopic examination:

Section shows polyp with acanthotic squamous epithelium underlying vascularised stroma with dilated lymphatics.

No evidence of granulomas / malignancy in section studied.

Comments: Features are S/o Benign fibroepithelial polyp

* Please correlate with clinical findings if necessary discuss.
☐ Slides enclosed
☐ Paraffin Blocks will be preserved for 3 years
☐ Specimen will be discarded after 15 days.

Verified By: DR HARISH MD PATH

Dr. A.V. Naidu MD PATH

MG - 277/A | Ground Floor | Remedy Hospital Lane | Road No. 4 Chowrasta
KPHB Colony | Hyderabad - 500 072 | Telangana | India.
040-48553410 | 91 5476 5476
<http://www.narayanaagnosticscityd.com>

**EXCISIONAL BIOPSY ON RIGHT
LATERAL PART OF TONGUE**